
Orthodontic Preparation for Orthognathic Surgery

Abdolreza Jamilian, Alireza Darnahal and
Letizia Perillo

Additional information is available at the end of the chapter

<http://dx.doi.org/10.5772/58957>

1. Introduction

Orthodontic treatment goals can be divided into five categories: facial esthetics, dental esthetics, functional occlusion, periodontal health, and stability.[1] Nevertheless, when a severe skeletal deformity exists in non-growing teen and adult patients with significant skeletal jaw discrepancy, the goals of treatment are often impossible to achieve by orthodontics alone. In these circumstances, both orthodontics and surgery are required to correct the dental malposition and the skeletal disharmony. This corrective jaw surgery, also called orthognathic surgery, is performed by oral and maxillofacial surgeons to correct a wide range of minor and major skeletal and dental irregularities, including the misalignment of jaws and teeth, which, in turn, can improve chewing, speaking and breathing. Orthodontics in conjunction with orthognathic surgery can do wonders in improving the appearance of the face. Combined orthodontic and surgical treatment usually requires about 18-24 months to complete. The treatment may be divided into four stages:

- a. Treatment Planning
- b. Presurgical Orthodontics
- c. Surgical Treatment
- d. Post-Surgical Orthodontics

2. Treatment planning

Proffit and Ackerman [2] introduced the concept of envelope of discrepancy to graphically illustrate four ranges of correction for any characteristics of malocclusion: (A) an amount that

can be accomplished by orthodontic tooth movement alone; (B) a larger amount that can be accomplished by orthodontic tooth movement aided by absolute anchorage; (C) an additional amount that can be achieved by functional or orthopedic treatment to modify growth;[3-5] and (D) a still larger amount that requires surgery as part of the treatment plan.

People who can potentially benefit from orthognathic surgery include those with jaws that are positioned incorrectly. Orthognathic surgery is also the treatment of choice in patients who have not had the benefit of dentofacial orthopedics for growth guidance, or in cases where the deformity is so severe that orthodontics alone is not enough to correct it. Achieving successful treatment outcomes in these patients requires implementing an effective treatment plan. It should be considered that treatment planning is one of the most important stages because once the treatment is started it is hardly possible to reverse or suspend it. At this stage, the patient should be verified to have no potential of growth. If the patient is still growing he or she should be examined annually until growth is complete. Once facial growth cessation is verified the patient should be referred to a multidisciplinary clinic for joint treatment planning with the maxillofacial surgeon and orthodontist. In the beginning information about patient's general health state and previous diseases is evaluated and if there are no contraindications for surgery and general anesthesia a thorough examination of the face including evaluation of facial and dental photographs, cephalometric radiographs, and dental casts should be done. Subsequently, the orthodontist and maxillofacial surgeon should make a joint decision concerning the treatment approach. One of the aspects for consideration is whether the surgery is required in the mandible, maxilla or both and whether the jaw is to remain in one piece or to be segmented.

3. Presurgical orthodontics

Orthodontic preparation for surgery is different from orthodontic correction alone. Achievement of optimal facial esthetics requires integrated cooperation of orthodontists and maxillofacial surgeons. Routine preoperative orthodontics involve dental alignment, incisor decompensation, and arch coordination for the purpose of obtaining maximum intercuspatal interdigitation when the jaws are surgically aligned. In short the aims of presurgical treatment are to decompensate lower and upper incisors, level and align both arches and relieve the crowding. In general these corrections will make the malocclusion look worse presurgically, but it will show the true magnitude of the skeletal problem thus allowing an optimal correction at surgery.[6] To sum up, the essential steps in orthodontic preparation for orthognathic surgery are to align the arches individually, achieve compatibility of the arches or arch segments, and establish the proper anteroposterior and vertical position of the incisors.

3.1. Dental alignment

Dental crowding, spacing, misalignment and rotations of the teeth should be corrected before orthognathic surgery. The key is to get the teeth in proper position and angulation. In this phase of the treatment, extractions might be needed to relieve moderate to severe crowding

and make needed space for teeth alignment. Extraction can also help remove dental compensations. It should be taken into consideration that extraction should be avoided if the space of the jaw permits favorable dental alignment. Incisor inclination, crowding, type of malocclusion and surgical procedure are among the determining factors in deciding which teeth should be extracted.

3.2. Decompensation

Most severe skeletal jaw discrepancies are partly compensated. This natural phenomena called “dentoalveolar compensation” is a system which attempts to maintain normal interarch relationship.[7]

Compensations can be dental or skeletal in nature. Dental compensations can be vertical, transverse and/or sagittal. The factors responsible for dentoalveolar adaptation include: a normal eruptive system, surrounding soft tissue pressures and the influence neighboring and opposing teeth during occlusion. For example in class II skeletal malocclusions the upper anteriors retrocline to compensate for maxillary prognathism and lower incisors procline to compensate for mandibular retrognathism. While in class II skeletal malocclusion the upper anteriors procline to compensate for maxillary retrognathism and lower incisors retrocline to compensate for mandibular prognathism.

In contrast to dental camouflage, in preparation for orthognathic surgery, it is necessary to remove any dental compensations present and to place the teeth in a favorable position with their supporting bone. This is called presurgical decompensation. Presurgical orthodontic decompensation is essential to enable the surgeon to make a considerable amount of surgical correction. Failure to fully remove anterior incisor compensations presurgically will limit the surgical correction, leading to compromised facial esthetics and occlusion. Such anteroposterior dental decompensation may involve specific extractions, anchorage needs, or use of class II/class III elastics. For example, decompensation of skeletal class II malocclusion will often require the use of class III elastics to upright lower incisors and decompensation of skeletal class III malocclusion necessitates the use of class II elastics to procline lower incisors and establish adequate reverse overjet.

Decompensation accentuates the patient’s deformity but is necessary for achievement of normal occlusal relationships when skeletal bones are properly positioned at surgery.

3.3. Arch coordination

Arch coordination refers to coordinating the widths of the dental arches so that there is a normal transvers relationship following sagittal jaw movements. Coordination often involves arch expansion, arch contraction, and occlusal plane leveling and alignment. Orthodontic expansion or contraction to coordinate the upper and the lower arches should be carried out prior to the surgical procedure in order to provide correct post-operative occlusal interdigitation. Poor arch coordination, particularly in the transverse or vertical plane, will restrict or destabilize jaw movements at the time of surgery and compromise postsurgical stability.

3.4. Presurgical orthodontics objectives in the transverse plane

Ideally, the width of maxilla should be slightly more than the mandible in order to produce normal buccal overjet. Transverse discrepancy happens when there is a defect in the widths of the arches. The maxilla is more commonly affected in this discrepancy which can be either unilateral or bilateral. This discrepancy is often combined with sagittal or vertical problems.

Pre-surgical orthodontic treatment consideration of transverse discrepancy:

i. The problem is the skeletal or dental

Dental discrepancies are usually treated by means of buccal tipping of the posterior teeth while skeletal discrepancies are corrected by bodily movement of the posterior teeth. If the posterior teeth are tipped lingually, presurgical orthodontic expansion (buccal tipping) should be used; however, the tipping should not exceed 4 to 6 mm total. Bodily movement of the posterior teeth should be done by means of segmental osteotomy, without the need for orthodontic expansion.

ii. Is the problem relative or absolute

Articulation of the casts into a class I occlusion allows the clinician to easily distinguish between relative and absolute maxillary constriction. If the occlusion is proper when the casts are brought into class I canine relationship the discrepancy is relative; otherwise, if a crossbite still exists, then the discrepancy is absolute. Absolute skeletal transverse discrepancy requires planning for segmental osteotomies or surgically assisted rapid palatal expansion (SARPE).[5]

SARPE technique is used in cases with a severe discrepancy or when the transverse defect of the maxillary bone is an isolated skeletal anomaly. While, segmental maxillary osteotomy is used for more modest defects (up to 7 mm) or when the transverse deficit is one of a number of maxillary skeletal deficits, including sagittal and vertical defects that would require surgical attention.[8]

3.5. Presurgical orthodontics objectives in the vertical plane

3.5.1. Open bite cases

Treatment of anterior open bite has always been a great challenge in orthodontics. Extrusion of anterior teeth and orthognathic surgery are among the possible options for treatment of open bite in non-growing patients. However, dental extrusion of skeletal open bite will be unstable in the long run. Furthermore, it may also create an excessive display of gingiva. Unaesthetic results and lack of stability of dental correction make surgery the treatment of choice for skeletal open bite cases. One of the chief considerations for treatment of these patients is the choice between one piece or segmented maxillary osteotomy. The decision for or against segmentation is made based on the patient's baseline skeletal deformity. These patients generally have an excessive curve of Spee in the upper jaw which is an indication of skeletal problem rather than a dental one. The severity of the curve of Spee indicates the need for segmental osteotomy. In other words, the more severe the curve of Spee, the more obvious the need for segmental osteotomy. When surgical segments are planned, the orthodontist's

role is to level presurgically within the segments but not across the osteotomy sites and to make sure that there is enough space between the roots of the involved teeth to allow interdental osteotomies.

Pre-surgical orthodontic treatment considerations in open bite cases:

- i. Avoid closing the anterior open bite presurgically by extruding the anterior teeth
 - ii. Avoid closing the anterior open bite presurgically by intruding the posterior teeth
 - iii. Accentuated or reversed curve of Spee should be levelled
- a. Leveling the maxillary arch:

In the presence of a flat curve of Spee with no vertical discrepancies within the arch, leveling is done with a continuous arch wire and the open bite can be corrected by a 1-piece Lefort I osteotomy. However, if a segmental Le Fort I osteotomy is planned for open bite correction, presurgical dental leveling and alignment should be carried out separately in each segment.

- b. Leveling the mandibular arch:

Since patients with open bite generally do not have severe reverse curve of Spee in the lower arch, continuous arch wire is used for complete leveling.

3.5.2. Deep bite cases

In patients with deep bite, there is nearly always an excessive curve of Spee in the lower arch and occasionally a reverse curve in the upper arch. In these cases, the curve of Spee is leveled intruding the incisors or extruding the posterior teeth. The decision to level by intrusion of the incisors or extrusion of the posterior segment depends on the initial facial height of the patients. As a general rule, the shorter the face height, the greater the need for extrusion.

3.6. Presurgical orthodontics objectives in the sagittal plane

3.6.1. Class II malocclusion

Skeletal class II malocclusion is naturally compensated to mask the skeletal discrepancy. This natural dental compensation involves retroclination of the upper incisors and proclination of lower incisors. The goals of presurgical orthodontics for these cases involve decompensation of these natural compensations along with alignment of teeth and establishing compatible arch forms.

Orthodontic decompensation of skeletal class II malocclusion cases involve proclining of retroclined upper incisors and uprighting the proclined lower incisors. This decompensation will increase the amount of overjet, which allows the maxillofacial surgeon to carry out maximum mandibular advancement and subsequently establish class I canine relationship after the surgery. (Figure 1)

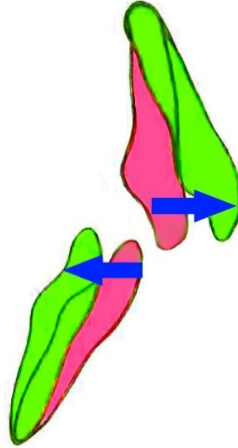


Figure 1. Orthodontic presurgical decompensation of class II malocclusion.

Alignment and leveling and the need for extraction in skeletal class II malocclusion cases depends on the degree of crowding. In crowded cases, extraction of upper second premolars and lower first premolars is a common orthodontic plan in preparation for surgical correction. The extraction of upper second premolars prevent further retroclination of upper incisors and the extraction of lower first premolars facilitate uprighting of lower incisors and subsequently establish enough overjet for surgery. We should bear in mind that extraction space should be closed before surgery

3.6.2. Class III malocclusion

In skeletal class III malocclusion cases the natural dental compensation involves proclination of the upper incisors and retroclination of lower incisors. Therefore, in these cases, orthodontic decompensation is achieved by uprighting the upper incisors and proclining the lower incisors and thereby increasing the reverse overjet to the maximum which would allow the surgeon to carry out maximum mandibular setback.

Similar to skeletal class II patients, in these cases also the alignment and levelling and the need for extraction depends on the degree of crowding. The usual pattern of extraction in these cases involves the extraction of upper first premolars in order to facilitate the uprighting of upper incisors and extraction of lower second premolars in order to prevent further retroclination of the lower incisors. These extractions also help to establish enough reverse overjet for the surgical procedure. Extraction space should also be closed before surgery. (Figure 2)

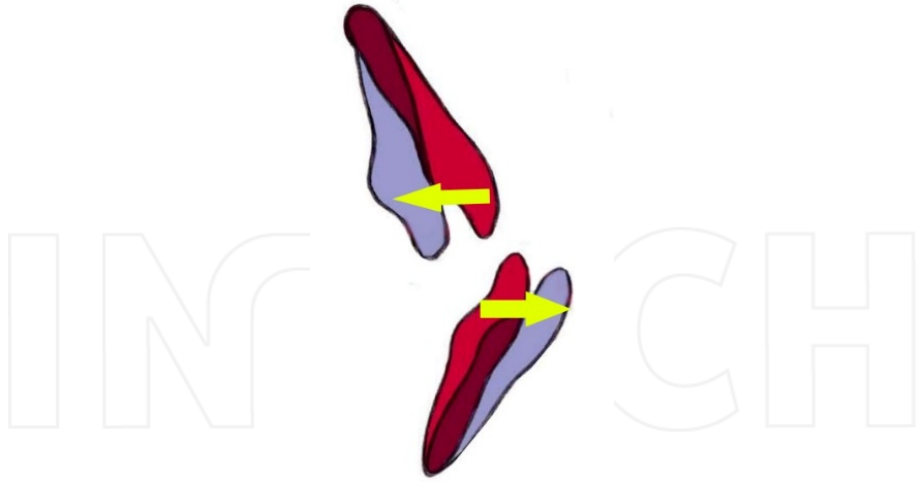


Figure 2. Orthodontic presurgical decompensation of class III.

4. Orthognathic surgery

Skeletal dentofacial deformities are associated with numerous problems including: esthetic, functional, psychological, speech, mastication, digestion, and possible temporomandibular joint dysfunctions.

Orthognathic surgery is a hospital based operation in which the elements of the facial skeleton are manipulated to restore the proper anatomic and functional relationship in patients with skeletal dentofacial deformities and overcome the above mentioned problems. The results of orthognathic surgery can have dramatic and positive effects on many aspects of the patient's life.

Orthognathic surgery is done through a variety of osteotomies including maxillary segmental osteotomies, Le Fort I maxillary osteotomy, Le Fort II osteotomy, Lefort III osteotomy, sagittal split osteotomy of the mandibular ramus, vertical ramal osteotomy, inverted L and C osteotomies, mandibular body segmental osteotomies, and mandibular symphysis osteotomies.

After the surgery, patients should expect the following:

- Swelling
- Nasal and sinus congestion
- Difficulty eating and chewing food for several weeks following surgery.

5. Post-surgical orthodontics

Approximately four to six weeks after surgery the patient should return to the orthodontist to begin post-surgical treatment. This short phase of orthodontic treatment postoperatively is necessary to detail the final occlusion and improve the stability of surgery. The goal is to settle the teeth in good occlusion and alignment and correct any possible skeletal relapse following surgery. Post-surgical orthodontics usually takes about six months and may involve use of intermaxillary elastics.

It is noteworthy to mention that precise and proper presurgical orthodontics minimize post-surgical orthodontics. After debanding and debonding the patients should be provided with upper and lower retainers.

5.1. Common mistakes in presurgical orthodontics

The orthodontist should avoid:

- Masking skeletal discrepancies by dental camouflage
- Closing the anterior open bite presurgically by extruding the anterior teeth in open bite cases
- Closing the anterior open bite presurgically by intruding the posterior teeth in open bite cases
- Aligning dental midlines in transverse plane discrepancy cases
- Correction of overjet in class II malocclusion cases
- Correction of reverse overjet in class III malocclusion cases

6. Summary

Successful treatment of patients who are candidates for orthognathic surgery requires close cooperation between the orthodontist and surgeon. Prior to surgery, the patients undergo orthodontic treatment in order to be prepared for corrective jaw surgery. Presurgical orthodontics involves dental decompensation, alignment of the dentition within the arches, leveling of the curve of Spee, and coordination of the maxillary and mandibular dentition. These steps vary from case to case based on the type of malocclusion and its severity.

7. Case report

7.1. Case summary

A 17 year-old boy with marked high angle skeletal class III malocclusion with severe maxillary retrognathia and mandibular prognathism. The patient had crowding in the upper jaw and

the lower incisors were tipped lingually due to Class III malocclusion compensation. Class III molar and canine relationship with posterior cross bite with high maxillary-mandibular plane angle and incompetent lips were noticeable. The patient did not complain from any TMJ signs or symptoms.

Examination of head and face

In the frontal plane the face of the patient had an elongated shape. Skeletal Class III pattern with severe maxillary retrusion, mandibular prognathism and concave profile.

Functional examination

The patient's path of closure showed no deviation. Maximum jaw opening was normal at 49 mm.

Intraoral examination

Severe Class III molar and canine relationship with 9 mm of reverse overjet. Anterior and posterior cross bite could be detected. Crowding was also seen in the upper jaw. The lower incisors were retroclined.

Mandibular arch: Good arch form; Lingual displacement of lower incisors.

Maxillary arch: Good arch form; crowding in the upper anterior segment

Occlusion (Sagittal): Severe Class III with reverse overjet of 9 mm; Very severe Class III molar and canine relationship on both sides

Occlusion (Vertical): Anterior open bite of 2 mm

Occlusion (Transversal): Upper midline coincided with facial midline; lower midline deviated 1 mm to the left

Cephalometric assessment

Cephalometric assessment shows skeletal Class III malocclusion with excessive growth of the mandible and reduced growth of the maxilla. The mandible was elongated. It also shows a degree of dento-alveolar compensation present in the lower anterior region. Upper incisors are positioned labially (Figure 3).

The patient's chief complaints:

- Severe maxillary deficiency
- Severe mandibular prognathism
- Crowding of upper arch

Treatment Plan:

Considering the severity of the malocclusion, the underlying skeletal discrepancy, age of the patient, a surgical-orthodontic approach was chosen.

The treatment plan was as follows:

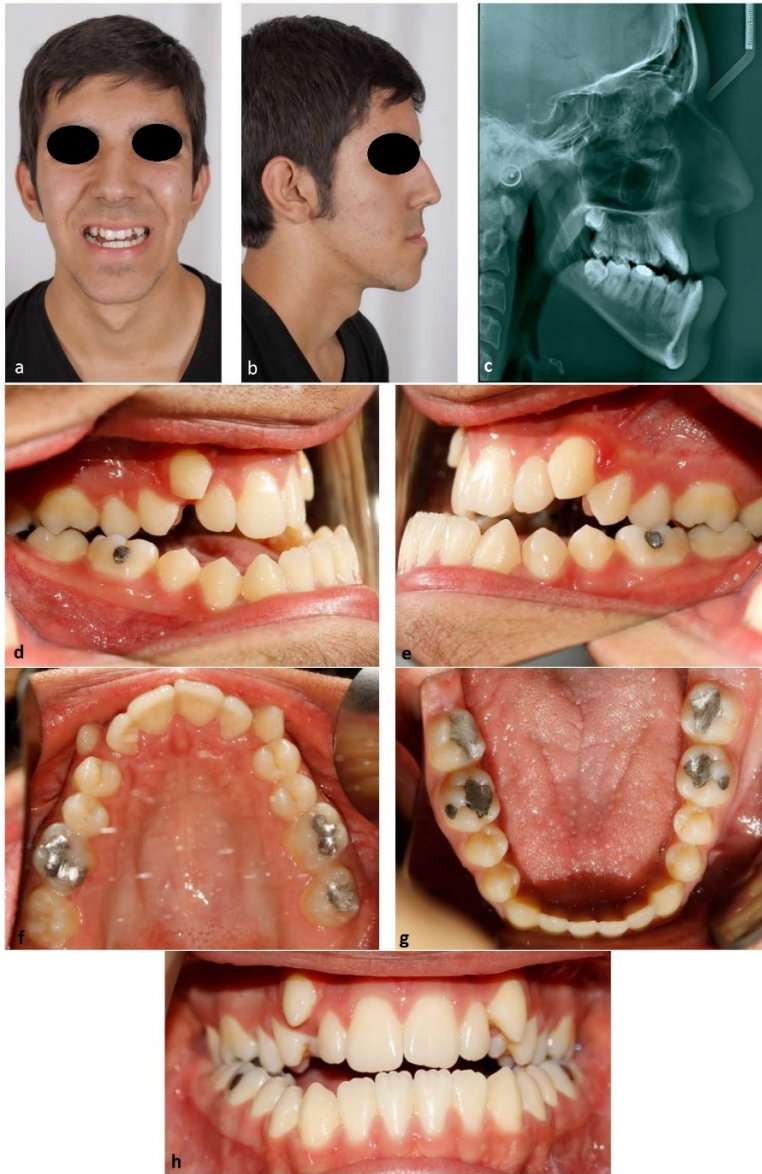

Figure 3. Before treatment records of an orthognathic surgery case with high angle skeletal class III malocclusion, severe maxillary retrognathia, lingually tipped lower incisors, upper crowding and mandibular prognathism.

- Levelling and aligning
- Decrowding

- Incisor decompensation by means of fixed appliance
- Bimaxillary surgery involving a maxillary advancement and impaction (Lefort 1), and a mandibular setback (bilateral sagittal split ramus osteotomy). Chin Augmentation.
- Post-surgical orthodontics: Arch coordination, detailing, suitable interdigitation
- Debonding
- Retention

8. Presurgical orthodontics

Upper removable appliance with a screw was fitted in the midline to expand the maxillary dentition and create space to relieve upper crowding. Upper and lower 0.018 standard edgewise fixed appliances were placed and the teeth were levelled and aligned. Class II elastics were used for decompensation of upper and lower incisors. At this stage the reverse overjet of the patient increased from 9 mm to 11 mm. Surgical wires were placed in the upper and lower jaws. After levelling, alignment, decrowding, decompensation and achieving increased reverse overjet, the patient was referred to the maxillofacial surgeon. (Figure 4)

9. Orthognathic surgery

- Maxillary advancement (6 mm)
- Maxillary impaction (4 mm)
- Mandibular setback (6 mm)
- Chin augmentation with Medpor®

10. Post-surgical orthodontics

After the surgery the patient had very mild paraesthesia in the lower lip. One month after the surgery postsurgical orthodontics was started by replacing surgical wires with 0.016 stainless steel wires. Class III elastics were placed and Torque adjustment was done in the upper and lower jaws. After debanding and debonding upper and lower Hawley appliances were placed.

The post-surgical cephalogram of the patient showed significant improvement of the upper and lower jaws. Facial profile was more balanced and had improved significantly. Advancement of the Maxilla and setback of the mandible were obvious in the cephalogram. Chin augmentation with Medpor® could also be seen in the cephalometric image. The patient had satisfactory positive overjet and overbite. Overall, a pleasing Class 1 occlusion had been achieved in the patient. (Figure 5)

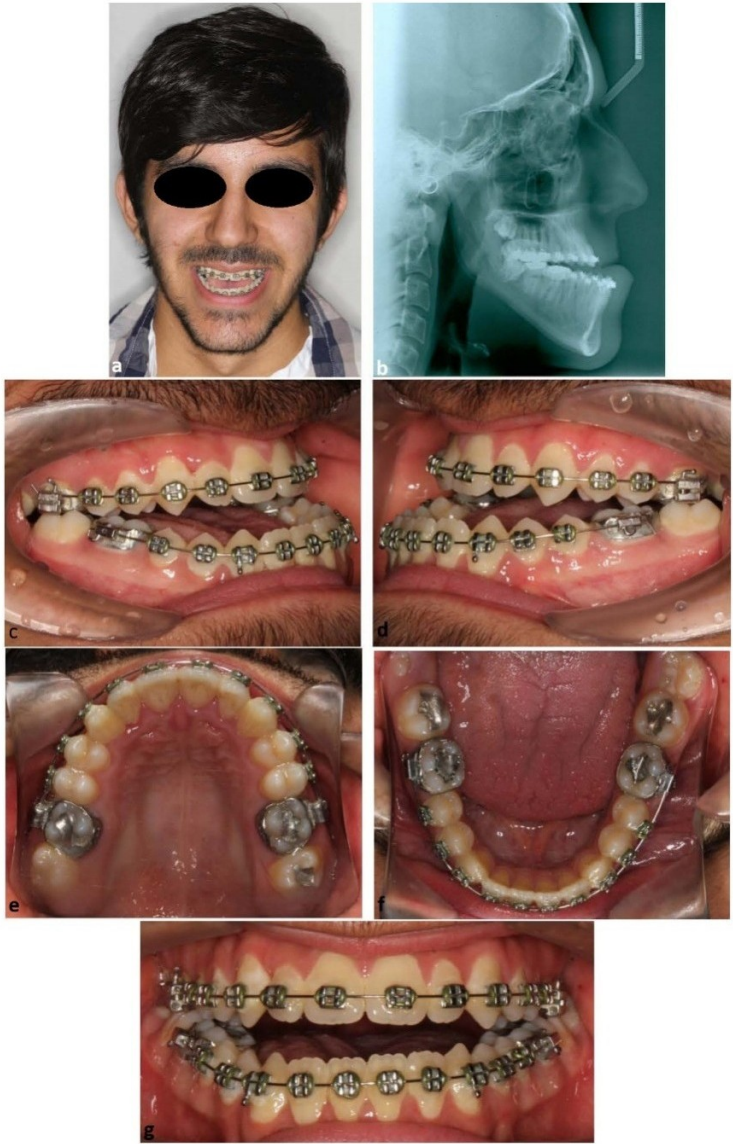


Figure 4. Presurgical orthodontics of the same patient. Upper and lower 0.018 standard edgewise fixed appliances

Intraoral examination showed that the patient had molar and canine class I relationship with no discrepancy between the jaws.

The intercuspatation was satisfactory and no signs of bruxism or other dysfunction was detected. The lips were competent and the patient was very satisfied with his appearance. No clicking or no signs and symptoms of temporomandibular dysfunction were noted.

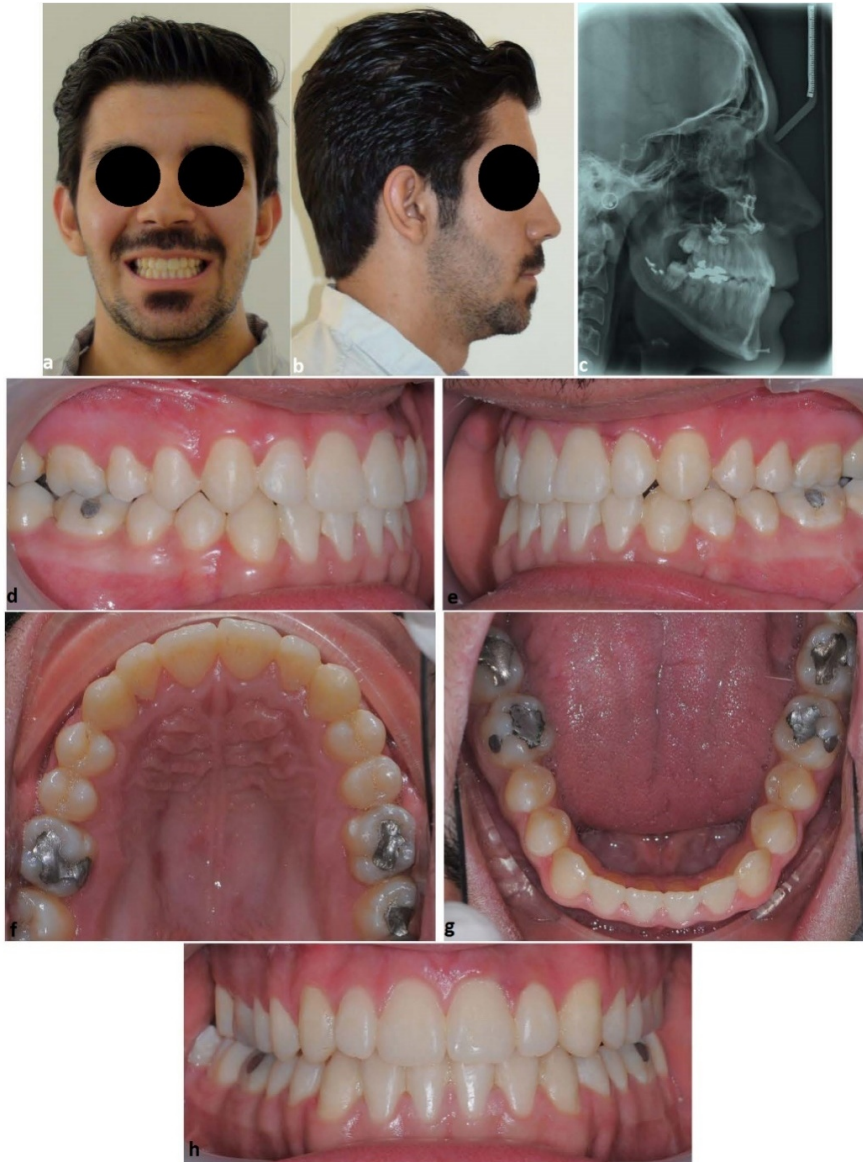


Figure 5. Same patient after surgery and retention

Author details

Abdolreza Jamilian^{1*}, Alireza Darnahal¹ and Letizia Perillo²

*Address all correspondence to: info@jamilian.net

1 Tehran Dental Branch, Department of Orthodontics, Islamic Azad University, Tehran, Iran

2 Departments of Orthodontics, Second University of Naples, Naples, Italy

References

- [1] Roth R. Roundtable: Diagnosis and treatment planning. *J Clin Orthod* 1992;26:585.
- [2] Ackerman JJ, Nguyen T, Proffit WR. The Decision-Making Process in Orthodontics. In: Graber TM, Vanarsdall Jr. RL, editors. *Orthodontics : current principles and techniques*. St. Louis, [Mo.]: Mosby; 2012.
- [3] Jamilian A, Haraji A, Showkatbakhsh R, Valaee N. The effects of miniscrew with Class III traction in growing patients with maxillary deficiency. *International journal of orthodontics*. 2011;22(2):25-30.
- [4] Showkatbakhsh R, Jamilian A, Ghassemi M, Ghassemi A, Taban T, Imani Z. The effects of facemask and reverse chin cup on maxillary deficient patients. *Journal of orthodontics*. 2012;39(2):95-101.
- [5] Suri L, Taneja P. Surgically assisted rapid palatal expansion: a literature review. *American journal of orthodontics and dentofacial orthopedics : official publication of the American Association of Orthodontists, its constituent societies, and the American Board of Orthodontics*. 2008;133(2):290-302.
- [6] Sabri R. Orthodontic objectives in orthognathic surgery: state of the art today. *World journal of orthodontics*. 2006;7(2):177-91.
- [7] Solow B. The dentoalveolar compensatory mechanism: background and clinical implications. *British journal of orthodontics*. 1980;7(3):145-61.
- [8] Marchetti C, Pironi M, Bianchi A, Musci A. Surgically assisted rapid palatal expansion vs. segmental Le Fort I osteotomy: transverse stability over a 2-year period. *Journal of cranio-maxillo-facial surgery : official publication of the European Association for Cranio-Maxillo-Facial Surgery*. 2009;37(2):74-8.