
Treatment Protocol for Skeletal Class III Malocclusion in Growing Patients

Jamilian Abdolreza, Khosravi Saeed and
Darnahal Alireza

Additional information is available at the end of the chapter

<http://dx.doi.org/10.5772/63095>

Abstract

Maxillary deficiency in growing patients with skeletal Class III malocclusion can be treated by either extraoral or intraoral appliances. Extraoral appliances include face mask, reverse chin cup, reverse headgear, and protraction headgear. Intraoral appliances include tongue appliance, fixed tongue appliance, tongue plate, Frankel III, miniplat in combination with Class III elastics, and miniscrew in combination with Class III elastics. Herein, we demonstrate our experience and treatment results in these patients.

Keywords: skeletal Class III malocclusion, maxillary deficiency, orthodontic treatment, growing patients, maxillary retrusion

1. Introduction

Skeletal Class III malocclusion is characterized by mandibular prognathism, maxillary deficiency, or some combination of these two features. The prevalence of Class III malocclusion varies among different ethnic groups. The prevalence in Caucasians ranges between 1% and 4%. A high prevalence has been reported in Asians. Various studies have reported that 4–12% of Chinese and 9–19% of Koreans suffer from Class III malocclusion which is relatively higher than 0.6–1.2% reported for African Americans and 6% reported for the Swedish population [1].

Approximately half of all skeletal Class III malocclusions are reported to result from maxillary deficiency. More precisely, the incidence of Class III malocclusions suffering from maxillary deficiency was reported to be 65–67% [2]. If the mandible of the patients is markedly affected, then the most common treatment would be orthodontics in combination with orthognathic surgery. In this chapter, the main focus of attention will be on maxillary deficiency in growing patients (pseudo-Class III).

In view of the high frequency of maxillary deficiency, maxillary advancement by orthopedic force is considered to be a viable treatment option in growing patients [3, 4]. A number of techniques have been described, including the use of a face mask [5–7], reverse chin cup [8], and direct force application through implants placed in the zygomatic processes [9]. It was also suggested that intentionally ankylosed teeth may be used as abutments for extraoral traction in patients with a severe disturbance in maxillary growth [10]. Miniscrew implants and miniplates have also been used to provide the necessary orthodontic anchorage in these cases [11–14]. The tongue plate and tongue appliance have also been used for the correction of maxillary deficiency in growing patients [15–17]. The mechanism of action associated with these appliances relies upon forward pressure from the tongue, which is transmitted via the appliance to the maxillary dentition and maxilla.

2. Treatment of maxillary deficiency in growing patients

Growing patients with skeletal Class III malocclusion characterized by maxillary deficiency can be treated by either extraoral or intraoral appliances. Extraoral appliances include face mask, reverse chin cup, reverse headgear, and protraction headgear and intraoral appliances include tongue appliance, fixed tongue appliance, tongue plate, Frankel III, miniplate in combination with Class III elastics, and miniscrew in combination with Class III elastics.

2.1. Extraoral appliances

2.1.1. Face mask

Face mask therapy has become a common technique used to correct the developing Class III malocclusion. A literature search will reveal extensive research on face masks and their effects on the nasomaxillary complex. In addition, the experimental studies constantly demonstrate pronounced forward movement of the maxilla due to heavy and continuous protraction forces of face masks [18]. Face masks were first described more than a century ago [19]. Delaire et al.'s [19] face mask promotes midface orthopedic expansion with slight inferior and anterior movement of the maxilla. The protraction face mask provides a direct constant anterior force to the maxilla with downward and backward rotation of the mandible [20]. Nanda introduced a modified protraction headgear that aimed to control the point and direction of force application [21] (**Figure 1**). Similar appliances to the face mask have been proposed by various clinicians and vary slightly from each other but their mechanisms are almost the same. Some

of these appliances are reverse headgear, front pull headgear, and protraction headgear among others.

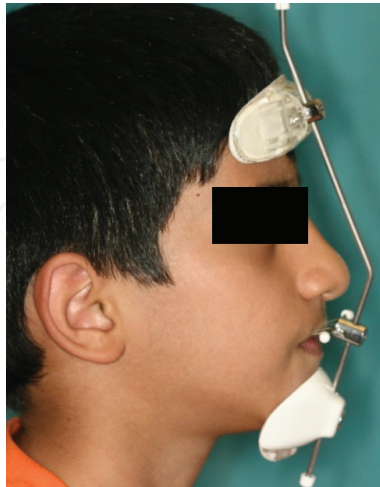


Figure 1. Face mask in situ; note forehead and chin pads, main bar, crossbar, and elastics connecting the crossbar to the maxilla.

2.1.1.1. Limitations

However, one of the problems with face masks is their bulky size and shape, which make it a discouraging choice for children. Patients who wear glasses will be especially more susceptible to discomfort. This discomfort along with the embarrassment caused by the large size, especially for children at school in front of other, may reduce patient compliance. The forehead and the chin are used as areas that support the face mask. Nanda reported that in face mask therapy although the maxilla will translate forward, downward and backward rotations of mandible are unavoidable [21]. The backward and downward rotations of the mandible are unfavorable in patients with vertical growth pattern. On the contrary, this effect may be favorable in patients with a horizontal growth pattern. Face mask would also cause forward movement of the maxillary dentition and lingual movement of the mandibular incisors [8].

2.1.2. Reverse chin cup

The chin cup is an extraoral appliance first introduced by Showkatbakhsh et al. [8, 22]. The reverse chin cup is composed of an upper removable appliance and a custom made porous acrylic chin cup with two vertical arms. The upper removable appliance consists of two Adams clasps on the permanent first molars, two C clasps on the primary canines, and two C clasps on the permanent central incisors. If necessary, the number of C clasps and Adams clasps can be increased for anchorage reinforcement. The end of each arm of the chin cup is bent to form

a hook. Two orthodontic latex elastics (recommended: 5/16, heavy elastics) connect the hooks of the palatal canine area of the upper removable appliance to the hooks of reverse chin cup in order to deliver approximately 500 g of force on each side. A high pull head cup is used to hold the reverse chin cup. The patients are instructed to wear the appliance full time except for eating, contact sports, and toothbrushing (**Figure 2**).

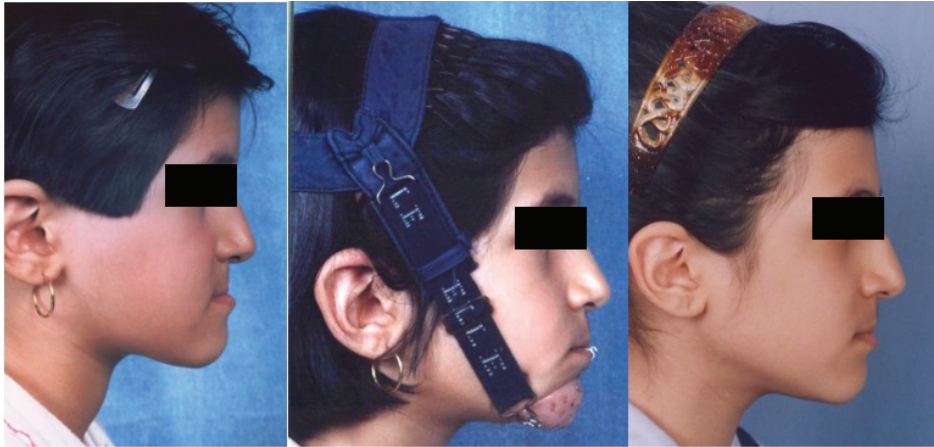

Figure 2. A 6-year-old patient in the mixed dentition with Class III malocclusion and maxillary deficiency. Concave profile was obvious. She had a reverse overjet and underbite. She was treated via reverse chin cup. After 18 months of treatment, her profile improved and a positive overjet was achieved.

The reverse chin cup is very similar to the face mask and is able to produce forward movement of the maxilla in growing patients; however, chin cup may be more favorable for patients due to its smaller size.

2.1.2.1. Limitations

Similar to face masks reverse chin cup is also associated with lingual tipping of the lower incisors and labial tipping of the uppers. Another drawback of the reverse chin cup is backward and downward rotation of the mandible.

2.2. Intraoral appliances

2.2.1. Removable tongue appliance

The tongue appliance is a habit breaker which is constructed via Adams clasps in the first upper molars and C clasps in the anterior teeth in order to increase retention. Three to five separate tongue cribs are placed in the palatal area from canine to canine. These cribs are long enough to cage the tongue and are adjusted to prevent traumatizing the floor of the mouth. A screw is mounted in the midpalatal area to correct bilateral posterior cross bite. The patients are instructed to tighten the screw once per week [15] (**Figure 3**).

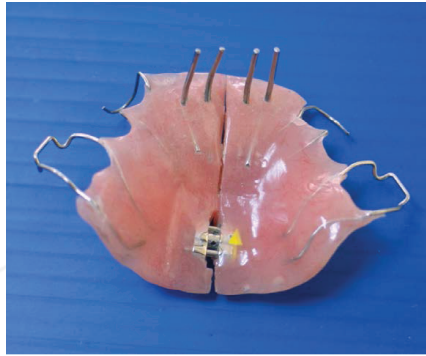


Figure 3. Tongue appliance.

When the tongue appliance is in the mouth, a considerable amount of pressure is transmitted to the deficient maxilla. The mechanism of this force is provided in two ways, namely:

The intermittent force is transferred through the tongue appliance to the deficient nasomaxillary complex via the pressure of the tongue during swallowing which is estimated to be about 5 pounds in each swallow. The frequency of swallowing is about 500–1200 times in 24 h.

Pressure to the tongue appliance transmits considerable force while it is in the rest position. This continuous force of the tongue pushes the maxilla into a forward position.

Physiological position and functional activity of tongue generate these forces. These forces are transmitted by the tongue through the palatal cribs and finally to the nasomaxillary complex. The more anterior the tongue is, the greater the force will be; the more posterior the crib is, the greater the force will be (**Figure 4**).

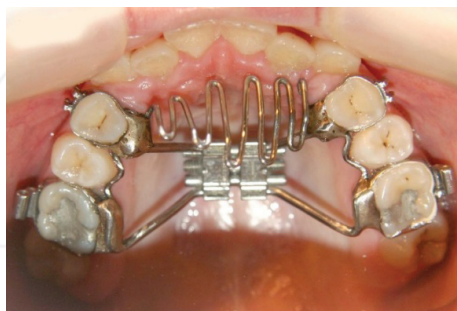

Figure 4. Fixed tongue appliance in situ.

Unlike extraoral appliances such as the face mask and reverse chin cup, the removable tongue appliance has no adverse effects on the mandible and would not cause its backward and

downward rotation. Another advantage of this appliance over the other extraoral appliances is that it is less conspicuous and needs less patient compliance.

2.2.1.1. Limitations

The removable tongue appliance will lingualize the lower incisors due to elimination of tongue pressure. In other words, after discontinuing the appliance, the IMPA will be increased and the overjet will be decreased [23]. Another disadvantage of removable tongue appliance is the need for patient cooperation and lack of compliance of which would have negative effects on the final result.

2.2.2. Fixed tongue appliance

In order to remove the need for patient compliance in removable tongue appliances, Showkatbakhsh et al. designed a new appliance called the “fixed tongue appliance” [24]. Fixed tongue appliances consist of a Hyrax® mounted on the first maxillary molars and premolars; a few curved cribs are soldered to the anterior side of the Hyrax® (**Figure 4**). The patient is instructed to activate the screw of the Hyrax® by making 1/4 of a turn at the beginning of each week. Fixed tongue appliance is a habit breaker used in conjunction with the Hyrax® for a different purpose other than its common application. The Hyrax® screw is for the purpose of loosening the maxillary sutures and extending the width of the maxillary arch and thus creating a better intermaxillary relationship. This expansion facilitates anterior displacement of the maxilla. When the fixed tongue appliance is in the mouth, a considerable amount of pressure is transmitted to the deficient maxilla through the cribs of the appliance. The mechanism of this force is similar to the removable tongue appliance (**Figures 5 and 6**). The fixed tongue appliance is used for the correction of skeletal problems and further treatment by fixed orthodontics is required for dental problems (**Figure 7**).

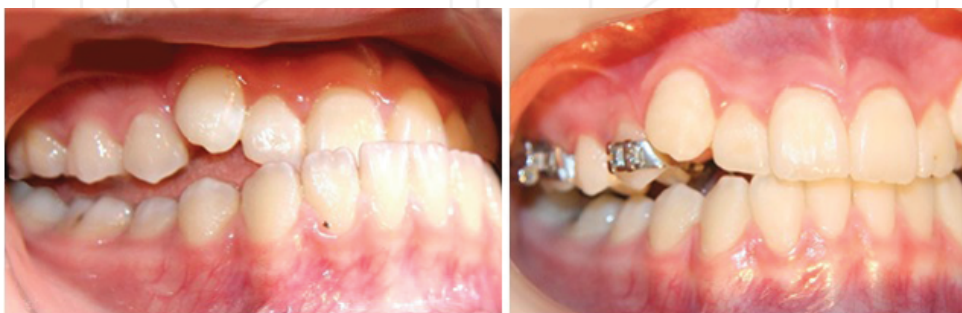

Figure 5. A 12-year-old girl with maxillary deficiency in the late mixed dentition and Class III molar and canine relationships. Skeletal problems of the patient were corrected by means of a fixed tongue appliance

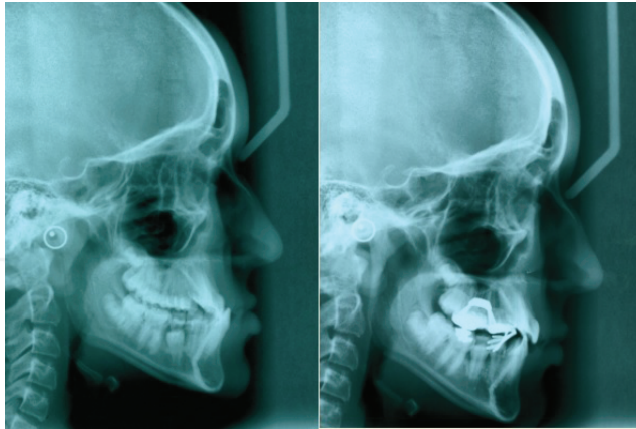


Figure 6. Pre- and post-treatment lateral cephalograms of the same patient.

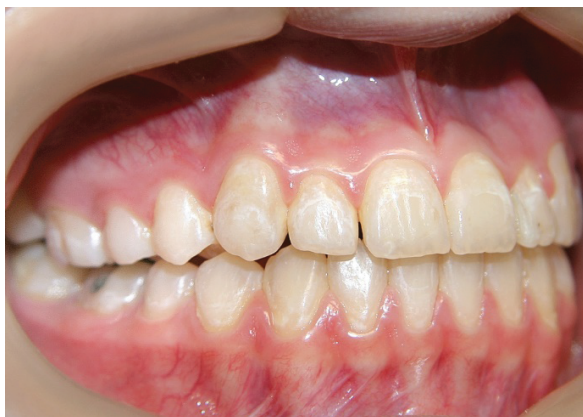

Figure 7. The occlusion of the same patient treated by fixed orthodontics.

One of the advantages of the fixed tongue appliance is that patient's cooperation is not needed. The vertical length of the cribs should be designed and adjusted in a way to avoid traumatizing the floor of the mouth. The main advantage of the fixed tongue appliance over the face mask is that the fixed tongue appliance does not cause backward rotation of the mandible; thus, it can be used in long-face patients, while the cup of the face mask results in backward rotation of the mandible and can have unfavorable effects in long-face patients [25].

2.2.2.1. Limitations

The fixed tongue appliance has one disadvantage. It will lingualize the lower incisors due to elimination of pressure of the tongue on them. However, removal of the fixed tongue appliance

will restore the pressure of the tongue on the lower incisors and will consequently result in the increase of the IMPA.

2.2.3. Tongue plate

The tongue plate is a tightly fitting and well-retained upper removable appliance fabricated with Adams clasps on the upper first permanent molars and C clasps placed on the upper primary canines [17]. Additional C clasps can be added if more retention is needed. An acrylic plate was mounted posterior to the upper incisors. The patients were instructed to wear the appliance full time except for eating, contact sports, and toothbrushing (**Figure 8**).

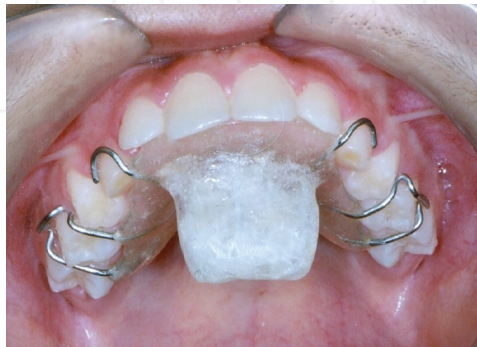

Figure 8. Tongue plate in situ.

The mechanism of action of the tongue plate is very similar to the fixed and removable tongue appliance. The force of the tongue during swallowing and resting is transferred through the tongue plate to the deficient nasomaxillary complex. The force of the tongue which is considerable is caged behind the acrylic plate and moves the maxilla in a forward position. The rounded surface of the plate and its softened edges make it undamaging for the tongue. In addition, it is designed and adjusted in a way to avoid traumatizing the floor of the mouth.

The disadvantages of the tongue plate are similar to those of fixed and removable tongue appliances in that it also lingualizes the lower incisors.

2.2.4. Frankel III appliance

The Frankel III appliance is a removable appliance used to stimulate the growth of the upper jaw and move it forward. The appliance was first designed by Professor Frankel and is composed of wire and four acrylic parts: two vestibular shields and two upper labial pads [26]. The vestibular shields extend from the depth of the mandibular vestibule to the height of the maxillary vestibule. These shields act to remove the restrictive forces created by the buccinator and associated facial muscles against the lateral surfaces of the alveoli and the buccal dentition. The appliance allows the maxillary molars to erupt and move mesially while holding the lower molars in place vertically and anteroposteriorly; it also tips the maxillary anterior teeth facially

and retracts the anterior mandibular teeth. Vertical movement of the maxillary molar will help rotate the chin down and back to improve facial appearance.

2.2.4.1. Limitations

The Frankel III appliance requires a lengthy treatment time and excellent patient cooperation.

2.3. Skeletal anchorage

Recently dental implants, miniplates, and modified fixation screws have become popular for bone anchorage in orthodontics. These temporary skeletal anchorage devices (TAD) are smaller than extraoral appliances and require short healing periods [27]. Various techniques have been developed to use miniplates and miniscrews as temporary anchorage devices. De Clerck et al. treated a series of Class III cases with orthopedic traction on miniplates [12].

2.3.1. Miniplate in combination with Class III elastics

Showkatbakhsh et al. [13] used Class III elastics connected from two mandibular miniplates to an upper removable appliance to treat an 11-year-old boy with maxillary deficiency. Plates for orthodontic anchorage were placed under local anesthesia in the canine areas of the mandible by a maxillofacial surgeon. The ideal position for miniplate insertion was evaluated by using a panoramic radiograph in order to avoid damage to the roots of the adjacent teeth and mental foramen. A tightly fitting and well-retained upper removable appliance was fabricated with two Adams clasps on the upper first permanent molars. Each of the Adams clasps had a loop which was used for retaining the elastics. A labial bow was also used on the anterior teeth for retention. A maxillary posterior bite plate was used to disocclude the upper and lower jaws. Orthodontic latex elastics (3/16" heavy size) were connected from the hooks of the miniplates to the Adams clasps of the removable appliance to generate approximately 500 g of anterior retraction. The patient was instructed to wear the appliance full time except for eating, contact sports, and toothbrushing; he was also told to change the elastics every day (**Figure 9**). After 10 months of active treatment, a positive overjet and Class I buccal segments were achieved and the anterior cross bite of the patient was corrected (**Figures 10 and 11**).

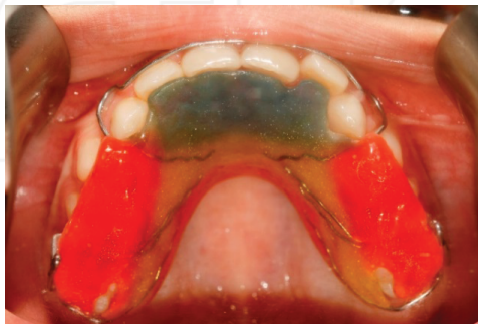

Figure 9. Miniplate in situ.

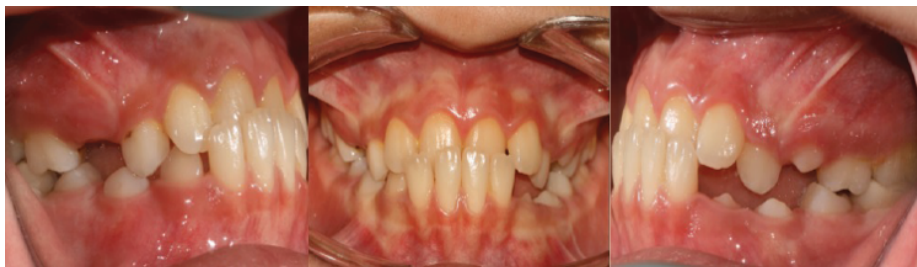

Figure 10. Pretreatment photos of an 11-year-old boy with pseudoprognathism (maxillary deficiency).

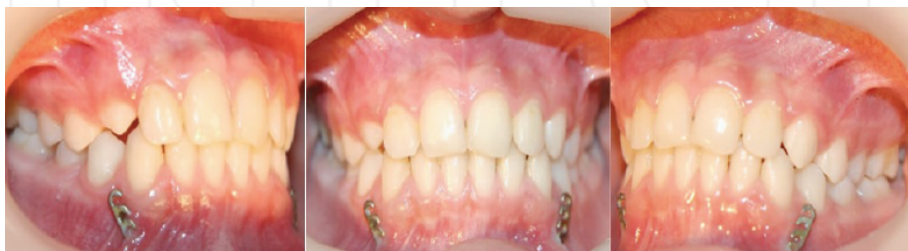

Figure 11. Posttreatment photos of the same patient treated by miniplates and Class III elastics.

2.3.1.1. Limitations

The need for minor surgery for inserting and removing the miniplates is their biggest disadvantage. Moreover, since the surgery involves flap elevation, it must be done by a maxillofacial surgeon under local anesthesia. Difficult oral hygiene around the appliance is another disadvantage of miniplates.

2.3.2. Miniscrews in combination with Class III elastics

Ease of placement, often by orthodontists themselves, has made miniscrews very popular. When used as orthodontic anchorage, they also have the advantage of fewer adverse effects and lower operational costs than tooth implants. Recently, Jamilian et al. used titanium alloy miniscrews along with Class III elastics for forward positioning of the maxilla of a patient with maxillary deficiency. In order to do so, self-drilling titanium alloy Jeil™ miniscrews (Jeil Medical Corp., Seoul, Korea; 1.6 mm diameter, 8 mm length) were placed under local anesthesia into the buccal alveolar bone between the mandibular canine and first premolar roots on both sides. The ideal position for screw insertion was evaluated by using a panoramic radiograph in order to avoid damage to the roots of the adjacent teeth and mental foramen. A tightly fitting and well-retained upper removable appliance was fabricated with Adams clasps on the upper first permanent molars and premolars. C clasps were placed on the upper permanent canines and central incisors. Orthodontic latex elastics (5/16" medium size) were

connected from the miniscrews to the Adams clasps of the removable appliance to generate about 450 g of anterior retraction. The patient was instructed to wear the elastics all the time, except for eating and to change the elastics every day. In order to retain these elastics, the Adams clasps on the molars and premolars were bent to form four loops; however in order to achieve optimal traction, the elastics were only connected to the loops adjacent to the molars (**Figure 12**).

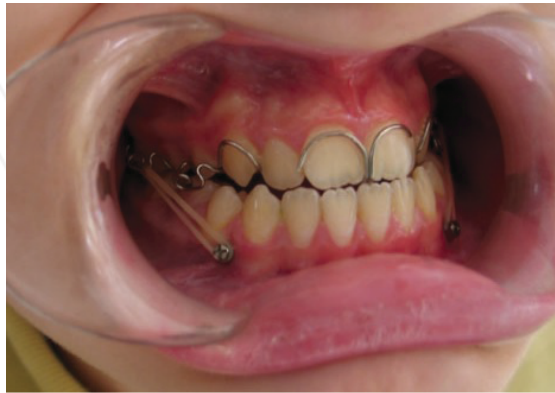

Figure 12. Miniscrews and Class III elastics.

An expansion screw was placed in the midpalatal area of the upper removable appliance and the patient was instructed to turn the screw once a week in order to correct the posterior cross bites. Two Z-springs were inserted in the upper removable appliance to correct the cross bite on the lateral incisors (**Figure 13**).

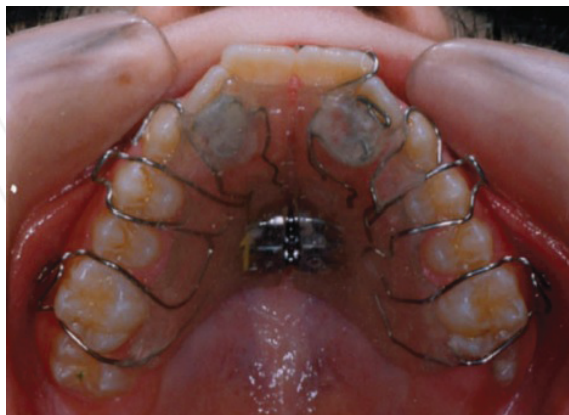

Figure 13. Expansion of the maxillary arch.

After 8 months of active treatment, a positive overjet and Class I buccal segments were achieved and the cross bites were corrected (**Figures 14 and 15**).

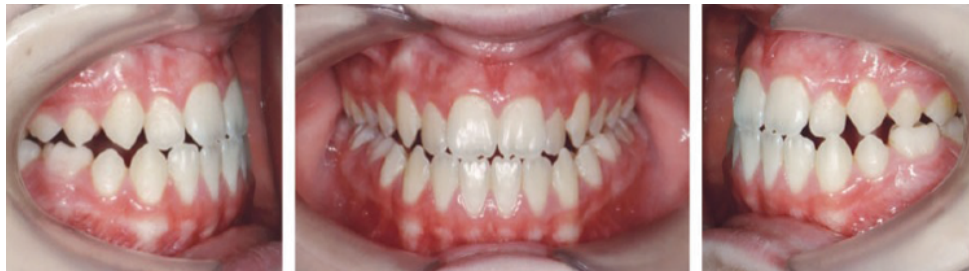

Figure 14. Pretreatment photographs of a 12-year-old boy with maxillary deficiency.

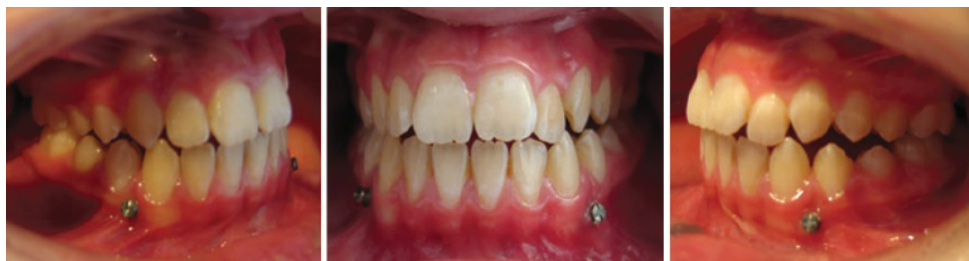

Figure 15. Post-treatment photographs of the same patient.

2.3.2.1. Limitations

The limitations of miniscrews include a high risk of failure when placed in unattached gingiva, screw loosening, tooth root injury when placed in keratinized mucosa, and limited amount and direction of tooth movement depending on the position of the miniscrews.

3. Conclusion

In growing patients with maxillary deficiency, maxillary advancement by orthopedic forces may be considered to be a viable treatment option. A number of techniques have been described, both intraoral and extraoral as well as direct force application through implants placed in the zygomatic processes with good results.

Author details

Jamilian Abdolreza^{1*}, Khosravi Saeed² and Darnahal Alireza³

*Address all correspondence to: info@jamilian.net

1 Department of Orthodontics, Islamic Azad University, Tehran Dental Branch, Cranio Maxillofacial Research Centre, Tehran, Iran

2 Tehran University of Medical Sciences, Tehran, Iran

3 Tehran Dental Branch, Islamic Azad University, Tehran, Iran

References

- [1] Ngan PW, Sung J-H. Chapter treatment strategies for developing and nondeveloping Class III malocclusions. In Nanda R editor. *Esthetics and Biomechanics in Orthodontics*, Second Edition. St Louis: WB Saunders.
- [2] Ellis E, 3rd, McNamara JA, Jr. Components of adult Class III open-bite malocclusion. *Am J Orthod* 1984;86:277–290.
- [3] Arman A, Toygar TU, Abuhijleh E. Profile changes associated with different orthopedic treatment approaches in class III malocclusions. *Angle Orthod* 2004;74:733–740.
- [4] Maspero C, Galbiati G, Perillo L, Favero L, Giannini L. Orthopaedic treatment efficiency in skeletal Class III malocclusions in young patients: RME-face mask versus TSME. *Eur J Paediatr Dent* 2012;13:225–230.
- [5] Delaire J, Verdon P. The use of heavy postero-anterior extraoral forces by an orthopedic mask in the treatment of dentomaxillary sequelae of labiomaxillopalatal clefts. *Chir Pediatr* 1983;24:315–322.
- [6] Jamilian A, Showkatbakhsh R, Taban T. The effects of fixed and removable face masks on maxillary deficiencies in growing patients. *Orthodontics (Chic.)* 2012;13:e37–43.
- [7] Perillo L, Vitale M, Masucci C, D'Apuzzo F, Cozza P, Franchi L. Comparisons of two protocols for the early treatment of Class III dentoskeletal disharmony. *Eur J Orthod* 2015;38:51–56.
- [8] Showkatbakhsh R, Jamilian A, Ghassemi M, Ghassemi A, Taban T, Imani Z. The effects of facemask and reverse chin cup on maxillary deficient patients. *J Orthod* 2012;39:95–101.
- [9] Singer SL, Henry PJ, Rosenberg I. Osseointegrated implants as an adjunct to facemask therapy: a case report. *Angle Orthod* 2000;70:253–262.

- [10] Kokich VG, Shapiro PA, Oswald R, Koskinen-Moffett L, Clarren SK. Ankylosed teeth as abutments for maxillary protraction: a case report. *Am J Orthod* 1985;88:303–307.
- [11] Jamilian A, Showkatbakhsh R. Treatment of maxillary deficiency by miniscrew implants—a case report. *J Orthod* 2010;37:56–61.
- [12] De Clerck HJ, Cornelis MA, Cevidanes LH, Heymann GC, Tulloch CJ. Orthopedic traction of the maxilla with miniplates: a new perspective for treatment of midface deficiency. *J Oral Maxillofac Surg* 2009;67:2123–2129.
- [13] Showkatbakhsh R, Jamilian A, Behnaz M. Treatment of maxillary deficiency by miniplates: a case report. *ISRN Surg* 2011;2011:854924.
- [14] Jamilian A, Haraji A, Showkatbakhsh R, Valaee N. The effects of miniscrew with class III traction in growing patients with maxillary deficiency. *Int J Orthod Milwaukee* 2011;22:25–30.
- [15] Jamilian A, Showkatbakhsh R. The effect of tongue appliance on the maxilla in Class III malocclusion due to maxillary deficiency. *Int J Orthod Milwaukee* 2009;20:11–14.
- [16] Showkatbakhsh R, Jamilian A. A novel method of maxillary deficiency treatment by tongue plate—a case report. *Int J Orthod Milwaukee* 2011;22:31–34.
- [17] Showkatbakhsh R, Toumarian L, Jamilian A, Sheibaninia A, Mirkarimi M, Taban T. The effects of face mask and tongue plate on maxillary deficiency in growing patients: a randomized clinical trial. *J Orthod* 2013;40:130–136.
- [18] Cha KS. Skeletal changes of maxillary protraction in patients exhibiting skeletal class III malocclusion: a comparison of three skeletal maturation groups. *Angle Orthod* 2003;73:26–35.
- [19] Delaire J, Verdon P, Lumineau JP, Cherga-Negrea A, Talmant J, Boisson M. Some results of extra-oral tractions with front-chin rest in the orthodontic treatment of class 3 maxillomandibular malformations and of bony sequelae of cleft lip and palate. *Rev Stomatol Chir Maxillofac* 1972;73:633–642.
- [20] Roberts CA, Subtelny JD. An American Board of Orthodontics case report. Use of the face mask in the treatment of maxillary skeletal retrusion. *Am J Orthod Dentofacial Orthop* 1988;93:388–394.
- [21] Nanda R. Biomechanical and clinical considerations of a modified protraction head-gear. *Am J Orthod* 1980;78:125–139.
- [22] Showkatbakhsh R, Jamilian A. A novel approach in treatment of maxillary deficiency by reverse chin cup. *Int J Orthod Milwaukee* 2010;21:27–31.
- [23] Showkatbakhsh R, Jamilian A, Taban T, Golrokh M. The effects of face mask and tongue appliance on maxillary deficiency in growing patients: a randomized clinical trial. *Prog Orthod* 2012;13:266–272.

- [24] Showkatbakhsh R, Jamilian A, Ghassemi M, Ghassemi A, Shayan A. Maxillary deficiency treatment by fixed tongue appliance—a case report. *Int J Orthod Milwaukee* 2013;24:31–34.
- [25] Showkatbakhsh R, Jamilian A, Behnaz M, Ghassemi M, Ghassemi A. The short-term effects of face mask and fixed tongue appliance on maxillary deficiency in growing patients—a randomized clinical trial. *Int J Orthod Milwaukee* 2015;26:33–38.
- [26] McNamara JA, Jr., Hulse SA. The functional regulator (FR-3) of Frankel. *Am J Orthod* 1985;88:409–424.
- [27] Cevidanes L, Baccetti T, Franchi L, McNamara JA, Jr., De Clerck H. Comparison of two protocols for maxillary protraction: bone anchors versus face mask with rapid maxillary expansion. *Angle Orthod* 2010;80:799–806.

